

The Appendicular Skeleton- Leg

Figure 5-11 is a diagram of the articulated pelvis.

Select different colors for the structures listed below and use them to color the coding circles and the corresponding structures in the figure. Using the Key Choices, write the letters on the line that correspond to the bones and bone markings. Finally, label the dashed lines showing the dimensions of the true pelvis and that showing the diameter of the false pelvis.

- Coxal bone
- Sacrum
- Pubic symphysis
- Acetabulum

Key Choices:

- A. Anterior superior iliac spine
- B. Iliac crest
- C. Ischial spine
- D. Obturator foramen
- E. Pelvic brim
- F. Pubic ramus

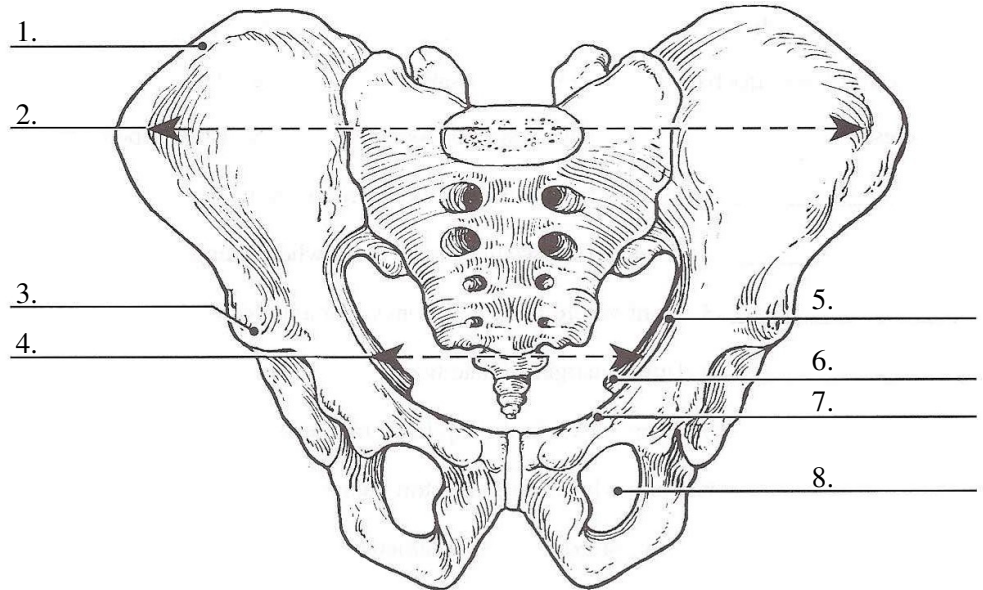


Figure 5-11

Using key choices, identify the bone names, according to the descriptions that follow. Insert the appropriate letter(s) in the answer blanks. Some letters may be used more than once.

- _____ 9. Fuse to form the coxal bone (hip bone)
- _____ 10. Point where the coxal bones join anteriorly
- _____ 11. Upper margin of iliac bones
- _____ 12. Point where axial skeleton attaches to the pelvic girdle
- _____ 13. Longest bone in body, articulates with the coxal bone
- _____ 14. Lateral bone of the leg
- _____ 15. Medial bone of the leg
- _____ 16. Bones forming the knee joint
- _____ 17. Kneecap
- _____ 18. Shinbone
- _____ 19. Heel bone
- _____ 20. Bones of the ankle
- _____ 21. Bones forming the instep of the foot
- _____ 22. Tarsal bone that articulates with the tibia

Key Choices

- A. Calcaneus
- B. Femur
- C. Fibula
- D. Iliac crest
- E. Ilium
- F. Ischium
- G. Metatarsals
- H. Patella
- I. Pubic symphysis
- J. Pubis
- K. Sacroiliac joint
- L. Talus
- M. Tarsals
- N. Tibia

Circle the term that does not belong in each of the following groupings.

- | | | | |
|---------------|----------|------------------|--------|
| 23. Tibia | Ulna | Fibula | Femur |
| 24. Skull | Rib cage | Vertebral column | Pelvis |
| 25. Ischium | Scapula | Ilium | Pubis |
| 26. Calcaneus | Tarsals | Carpals | Talus |

The bones of the thigh and the leg are shown in Figure 5-12. Identify each and put your answers in the blanks labeled A, B, and C. Select different colors for the lower limb bones listed below and use them to color in the coding circles and corresponding bones on the diagram. Use the Key Choices to complete the illustration by inserting the letter indicating bone markings.

- Femur
- Tibia
- Fibula

Key Choices:

- | | |
|-----------------------------|---------------------------|
| A. Anterior border of tibia | E. Intercondylar eminence |
| B. Greater trochanter | F. Lateral malleolus |
| C. Head of femur | G. Lesser trochanter |
| D. Head of fibula | H. Medial malleolus |
| | I. Tibial tuberosity |

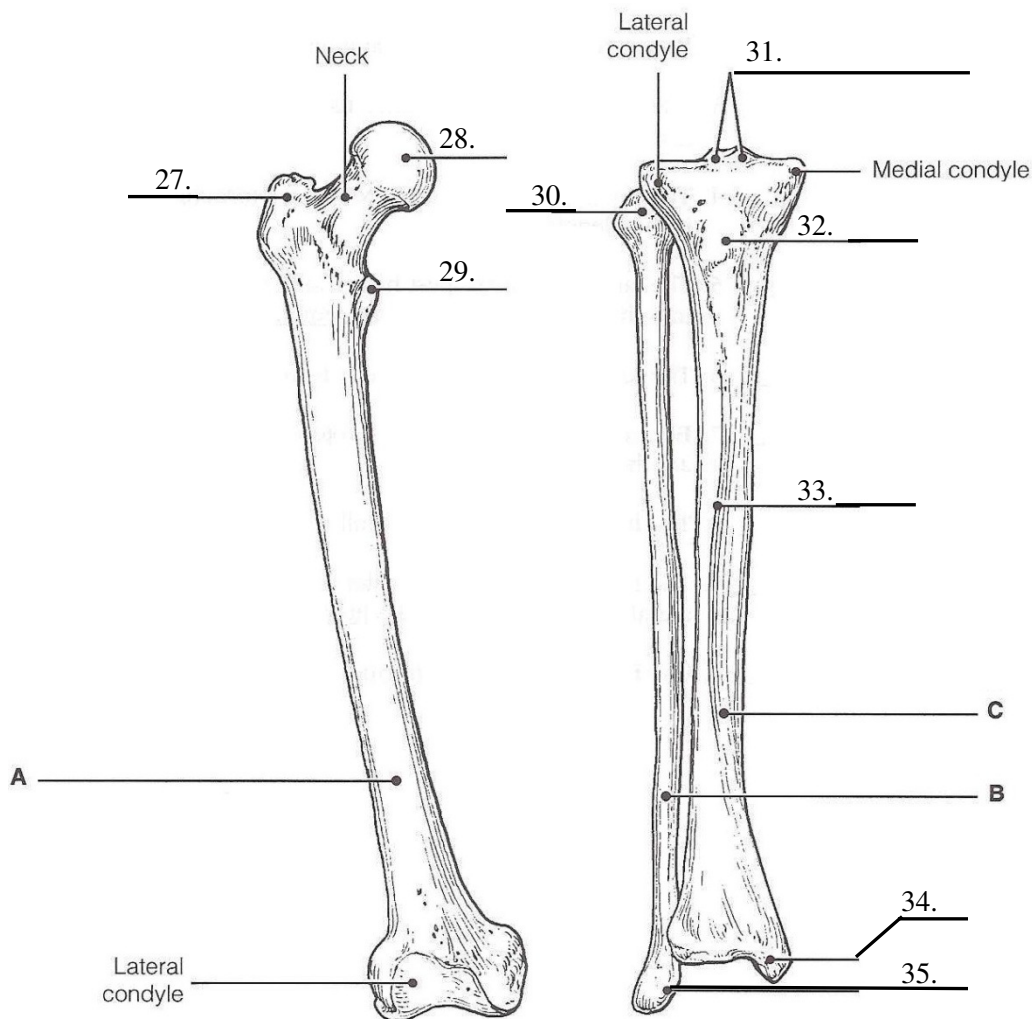


Figure 5-12